

Effects of Fluorides with and without Vitamin E on Body and Liver Weight of Adult Albino Mice

Inam F¹. and Shahid M².

¹Department of Anatomy, Akhtar Saeed Medical and Dental College, Lahore-Pakistan.

²Services Institute of Medical Sciences, Lahore -Pakistan.

ABSTRACT

Background and Objective: Fluoride salts generate free oxygen radicals which cause toxicity and effects on body organs. Toxicity due to fluoride is shown as decrease in body weight and organ weight. The present experimental study is designed to investigate the effects of sodium fluoride on body weight and weight of liver of mice and evaluate the protection provided by vitamin E.

Methods: A total of 48 male adult albino mice were divided in to four groups. Group A was given olive oil 6.67 ml/kg/day orally for 30 days. Group B was given sodium fluoride (NaF) 10 mg/kg/day dissolved in distilled water + olive oil 6.67 ml/kg/day both orally for 30 days. Group C was given sodium fluoride 10 mg/kg/day dissolved in distilled water and vitamin E 15 mg/kg/day dissolved in olive oil both orally for 30 days. Group D was given vitamin E 15 mg/kg/day dissolved in olive oil orally for 30 days. Weight of animals was recorded at the start and end of experiment. Animals were sacrificed and their livers were dissected out and weighed.

Results: Animals which received sodium fluoride showed decreased body weight and liver weight as compared to animal group A which received only olive oil ($P < 0.001$ and 0.001 respectively). Co-administration of vitamin E and sodium fluoride to animals of group C showed statistically significant prevention of decrease in body weight and liver weight as compared to the group which received sodium fluoride, $P < 0.001$.

Conclusion: Fluoride induced toxicity manifested as decrease in body weight and liver weight was effectively prevented by co-administration of Vitamin E treatment.

KEYWORDS: Sodium Fluoride, Body weight, Liver weight, Vitamin E.

INTRODUCTION

Fluorides are known to prevent tooth decay.¹ They are added as supplements in drinking water but in some places, they are found in high concentration in ground water.²

It has been found in many studies that fluorides exert adverse effects on human health. It affects soft tissues of body producing different pathologies.³ Toxicity can be acute with various symptoms including pain in abdomen, loose stools, vomiting, excess of Salivation and increased thirst.⁴ Long term exposure to fluorides results in dental and skeletal fluorosis which is documented as side effects.⁵ Various other organs in the body are also affected by the persistent exposure of the fluorides. Fluorides are reported to cause derangement in structure and functions of kidney, brain, testes, ovaries and thyroid gland.⁶⁻¹² Studies reported that there was significant reduction in body weight of experimental animals that were treated with sodium fluoride.¹³ In another study the reduction in body weight observed in experimental groups in down comparison to control rats was due to excessive break

of tissue proteins.^{14,15}

Liver as a vital organ in the body is affected by various doses of fluoride in experimental animal.¹⁶⁻¹⁸ Organ weight were reported to be reduced due to fluoride toxicity in animal models.^{19,20} It has been found that there is significant reduction in liver weight of rats treated with 100 ppm sodium fluoride (Naf) for 4 wee-ks.²¹

The likely mechanism of toxicity is due to increased production of reactive oxygen species and free radicals.^{7,16,17,22} Alpha tocopherol functions mainly as antioxidant. It has been shown that the alpha tocopherol interrupts free radicals and prevents a chain react-ion of lipid destruction in rats, apart from conserving the integrity of cell membrane throughout the body it protects the fat of low density lipoprotein from oxidation.²³ Alpha tocopherol is known to inhibit the activity of protein kinase C, and important cell signaling molecule to affect the expression and activity of immune and inflammatory cells.²⁴ The toxic effects of fluorides on the body weight and liver weight had been studied in the past along with the effect of

antioxidants in ameliorating the fluoride induced toxicity, but there is not ample data regarding the protection given by vitamin E on fluoride induced effect on weight of animal and organ weight. The present study therefore, aimed to investigate the changes in the weight of animals and weight of their liver in sodium fluoride treated mice and evaluate the protection provided by vitamin E.

METHODS

The study was carried out at University of Health Sciences Lahore and was approved by Ethical committee and Institutional Review Board. It was a randomized controlled experimental research. Forty-eight adult male Swiss albino mice 6 – 8 weeks old and weighing 30 ± 5 gm were obtained. They were divided into four groups A, B, C and D of 12 animals each. Animals were selected by simple random sampling technique. Only active and healthy-looking mice were chosen.

The animals were kept in cages at $23 \pm 2^{\circ}\text{C}$, humidity of $50 \pm 5\%$ and light and dark cycles of 12 hours. Animals were fed on standard pallet diet and were given water *ad libitum*. They were allowed to acclimatize for a week before starting the experiment. After acclimatization, the body weight of each animal was recorded as their initial weight on the digital weighing scale digital balance (Sartorius, model TE-214-S). Weight of the animals was taken at fixed time in the morning. Then it was recorded weekly for 4 weeks.

Group A was given olive oil 6.67 ml/kg/day orally for 30 days.

Group B was given sodium fluoride (NaF) 10 mg/kg/day dissolved in distilled water + olive oil 6.67 ml/kg/day both orally for 30 days.

Group C was given sodium fluoride 10 mg/kg/day dissolved in distilled water and vitamin E 15 mg/kg/day dissolved in olive oil both orally for 30 days.

Group D was given vitamin E 15 mg/kg/day dissolved in olive oil orally for 30 days.

All the treatments were given orally for 30 days. The weight of animals was recorded at the 31st day and they were sacrificed. Livers were dissected out and weighed.

STATISTICAL ANALYSIS

SPSS 18.0 was used for statistical analysis. For quantitative variables Mean (\pm S.D) was calculated. One Way ANOVA was applied to show the statistical difference in means of the four groups. The Post hoc Tukey test was applied to evaluate the difference of means between the groups. P value ≤ 0.05 was taken as statistically significant.

RESULTS

Mice in all the groups remained active throughout the experimental period except those of group B who

appeared to be slow later in their course of treatment.

The mean body weight of group A, B, C and D at the start and at the end of the experiment is shown in the bar charts in figure 1 and 2.

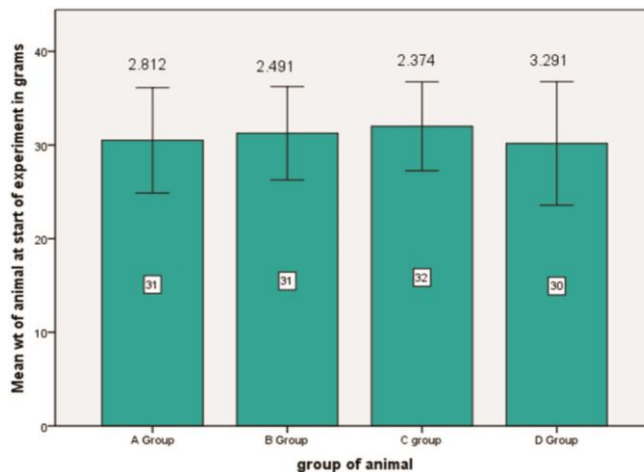


Fig. 1: Bar chart showing comparison of mean body weight (gm) and SD among groups at the start of experiment.

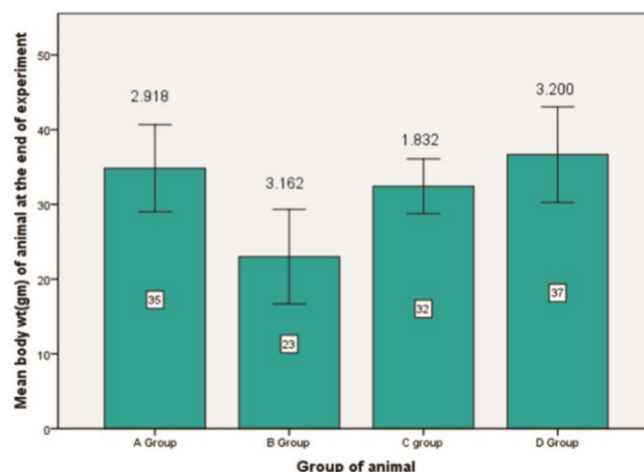


Fig. 2: Bar chart showing comparison of mean body weight (gm) and SD among groups at the end of experiment.

No significant difference was observed in mean body weight at the start of experiment. A significant difference in mean body weight was observed at the end of experiment (Fig.2). After applying Post hoc Tukey's test, statistically significant difference was observed between groups A and B, B and C, B and D, A and C and C and D while insignificant difference was observed between group A and D at the end of experiment (Table-2).

The livers of mice from all groups of animals were reddish brown in color and had four lobes, showing no abnormality in the color and texture; they were located

in the right upper quadrant of the abdominal cavity and were invested by a delicate connective tissue capsule, which was not adherent to the underlying liver tissue.

Table- 1: Post hoc Tukey’s test, showing comparison of body weight among groups at the end of experimental period.

Groups	Groups	Mean Difference	P-value
Group A	Group B	9.833	0.001
	Group C	3.417	0.025
	Group D	0.500	0.398
Group B	Group A	9.833	0.001
	Group C	9.417	0.001
	Group D	9.333	0.001
Group C	Group A	3.417	0.025
	Group B	9.417	0.001
	Group D	4.250	0.003
Group D	Group A	0.500	0.398
	Group B	9.333	0.001
	Group C	4.250	0.003

Table- 2: Post hoc Tukey’s test, showing comparison of liver weight among groups.

Groups	Groups	Mean Difference	P-value
Group A	Group B	0.61667	0.001
	Group C	0.22500	0.050
	Group D	0.01750	0.179
Group B	Group A	0.61667	0.001
	Group C	0.39167	0.001
	Group D	0.79167	0.001
Group C	Group A	0.22500	0.050
	Group B	0.39167	0.001
	Group D	0.40000	0.001
Group D	Group A	0.01750	0.179
	Group B	0.79167	0.001
	Group C	0.40000	0.001

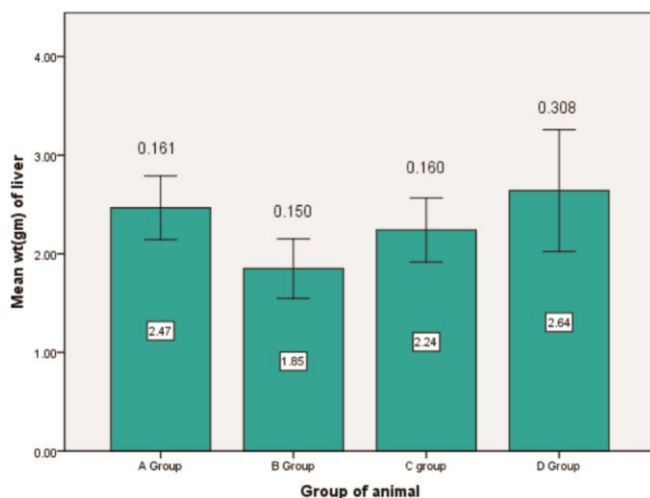


Fig. 3: Bar chart showing comparison of liver weight (gm) and SD among groups.

Mean liver weight ± SD of mice in grams for groups A, B, C and D were shown in the figure no. 3. After applying Post hoc Tukey’s test a significant difference was observed between group A and B, B and C, B and D, A and C and C and D (Table-2). Insignificant difference was observed between groups A and D (Table-2).

DISCUSSION

Body weights of the animals was significantly reduced in the experimental mice of group B as compared to the animals of group A (Table-1). The animals treated with fluoride and vitamin E in group C showed that body weight of the animals improved statistically significantly when compared to group B but improvement in weight was statistically insignificant in group C as compared to group A and D (Table-2).

These results were supported by previous studies on various animals; it was reported that exposure to fluoride 442 mg/kg/diet for 120 days significantly reduced the body weight of rabbits from 1.672 ± 0.173 kg in control group to 1.457 ± 0.184 kg in fluoride treated group.¹⁵ It has also been reported that the rats exposed to 200 and 400 ppm NaF for 30 days showed a statistically significant decrease in body weight when compared to that in the control group²⁶; decrease in body weight was presumed to be due to toxic effect on organ systems and decreased production of proteins.²⁷ The protein levels were significantly reduced due to decrease in food consumption and its malabsorption because of gross pathological changes in the digestive tract.²⁸ Arpita and Bidyut, (2012) showed that 10,15 and 20 ppm of sodium fluoride treatment to rats for 60 days did not show any statistically significant change in the body weight.²⁰ Chattopadhyay *et al.*, 2011 also reported no statistically significant difference in body weight of experimental mice with 15 mg/kg sodium fluoride for 30 and 90 days and 150 mg/kg sodium fluoride for 30 days.²⁹

Chinoy and Sharma, (1998) reported significant improvement in controlling body weight reduction of male mice by supplementation of vitamin E (2µg/day/animal for 30 days during the withdrawal period of NaF (10 mg/kg body weight for 30 days).²⁵ Verma and Sherlin, (2002) also showed that pregnant rats treated with sodium fluoride 40 mg/kg along with vitamin E 2mg/0.2ml olive oil/kg for 15 days of gestation from day 6 to day 21 caused significant amelioration in reduction of the body weight of pregnant rat.³⁰ The results of this study differ from these studies and it may be due to decrease dose of vitamin E and the fact that sodium fluoride and vitamin E were given simultaneously.

The results showed that weight of the liver in the fluoride treated group of mice decreased; statistically significant difference was observed in the weight of liver when compared to control group A. In present investigation group C animals showed significant improvement in weight of liver when compared to group B. (Table-2) but not significant when control groups A and D were compared (Table-2).

Vasant and Narasimhachaya, (2012) and Arpita and Bidyut, (2012) also reported reduction of liver weight in fluoride treated rats when compared to the controls; they presumed it to be due to direct effect of fluoride on target organs.^{21,20} Tsunoda *et al.*, (2005) reported no significant difference in liver weight of fluoride treated and control group of mice.³¹ Humayun, (2013) also reported significantly decreased liver weight with isoniazid toxicity in the form of ballooning degeneration, necrosis and congestion in liver.³²

CONCLUSION

It is concluded that reduction of weight of animal and weight of liver by fluoride occurs; results also have shown that vitamin E is effective in preventing changes in body weight and organ weight reduction.

LIMITATIONS OF STUDY

This study focusses only on the weight changes in body weight and liver. Histological and biochemical tests may have been applied to support the findings.

ACKNOWLEDGEMENT

The authors would like to express their sincere thanks to Mrs. Bushra Munir and Mr. Rizwan Ali for their assistance in Laboratory work and Mr. Asghar for taking care of the experimental animals in the research lab.

AUTHOR'S CONTRIBUTION

FI: Substantial contributions to conception and design, Analysis and interpretation of data, drafting

the article and final approval of the version to be published.

MS: Acquisition of data, drafting the article and revising it critically for important intellectual content and final approval of the version to be published.

CONFLICT OF INTEREST

None to declare.

GRANT SUPPORT AND FINANCIAL DISCLOSURE

The research was funded by University of Health Sciences, Lahore, Pakistan as a part of M.Phil project.

REFERENCES

1. National Cancer Institute Centers for Disease Control and Prevention. Public Health service report on fluoride benefits and risks. *JAMA*. 1991; 266(27): 1061-7.
2. Takizawa S. Ground water management in Asian cities: technology and policy for sustainability Springer. *Sci Bus Med*. 2008; 2 (2): 299-300.
3. Hanan B, Sabeur K, Kamel J, Tahia B, et al. Effects of sodium fluoride on hepatic toxicity in adult mice and their suckling pups. *Elsevier Pestic Biochem Physiol*. 2006; 86 (3): 124-30.
4. Dhar V, Bhatnagar M. Physiology and toxicity of fluoride; A review article. *Ind J Dent Res*. 2009; 20(7): 350-5.
5. Bertram G, Susan KB, Anthoy J. Basic and clinical Pharmacology. McGraw Hill Education. 12th edition, 2012: 777.
6. Shashi A, Singh JP, Thaper SP. Toxic effects of fluoride on rabbit's kidney. *Fluoride*, 2002; 35 (1): 38-50.
7. Shivarajashankara YM, Shivashankara AR, Gopalkrishna P, et al. Histological study of effects of fluoride on mice brain. *Fluoride*. 2002; 35 (1): 12-21.
8. Susheela AK, Bhatnagar M, Vig K, Mondal NK. Excess fluoride ingestion and thyroid hormone derangements in children living in Delhi, India. *Fluoride*. 2005; 38 (2): 98-108.
9. Bouaziz H, Ahela E, Ketata S, Jamoussi K, et al. Effect of Fluoride ingested by lactating mice on the thyroid function and bone maturation of their suckling pups. *Fluoride*. 2004; 37 (2): 133-42.
10. Gupta RS, Khan TI, Agrawal D, Kachhawa JB. The toxic effects of sodium fluoride on the reproductive system of male rats. *Toxic Ind Health*. 2007; 23 (9): 507-13.
11. Kumari M, Kumari S, Kumar A. A Study on the adverse effect of sodium fluoride upon the uterus of female albino rat using light microscopy. *Asian J Exp Biol Sci*. 2011; 2(4): 182-5.
12. Pushpalatha T, M. Srinivas, Sreenivasulu P. Exposure to high fluoride concentration in drinking water will affect spermatogenesis and steroidogenesis in male albino rats. *Biometals*. 2005; 18 (3): 207-12.
13. Vani ML, Reddy KP. Effects of fluoride accumulation on some enzymes of brain and gastrocnemius muscle of mice. *Fluoride.*, 2014; 33 (1): 17-26.
14. Chatterjee MN, Shinde R. Text book of Biochemistry. Jaypee Brothers Medical Publishers. New Delhi. 8th ed. 2002: 314-21.

15. Liang Z, Niu R, Wang J, Wang H, et al. Ameliorative effect of protein and calcium on fluoride-induced hepatotoxicity in rabbits. *Afr J Biotechnol.* 2012; 11 (3): 1301-8.
16. Chinoy NJ, Sharma AK, Patel TN. Recovery from fluoride and aluminum induced free radical liver toxicity in mice. *Fluoride.* 2004; 37 (4): 257-63.
17. Shivarajashankara YM, Shivashankara AR, Gopalkrishna Bhat P, et al. Effects of fluoride intoxication on lipid peroxidation and antioxidant systems in rats. *Fluoride.* 2001; 34 (2): 108-13.
18. Guo X, Sun G, Sun Y. Oxidative stress from fluoride induced hepatotoxicity in rats. *Fluoride.* 2003; 36 (1): 25-9.
19. Sharma JD, Sharma MK, Agrawal P. Effect of fluoride contaminated drinking water in albino rats *rattus norvegicus* Asian J Exp Sci. 2004; 18 (1): 37-46.
20. Arpita S, Bidyut B. Effect of fluoride toxicity on some clinical, biochemical and physiological aspects of albino rats. *Int J Res Chem.* 2012; 2 (1): 160-5.
21. Vasant RA, Narasimhacharya AVRL. Ameliorative effect of tamarind leaf on fluoride-induced metabolic alterations. *Environ Health Prev Med.* 2012; 17 (6): 484-93.
22. Liu G, Chai C, Cui L. Fluoride causing abnormally elevated serum nitric oxide levels in chicks. *Environ Toxicol Pharmacol.* 2003; 13 (3): 199-204.
23. Ramanathan K, Anusuyadevi M, Shila S, PanneerSelvam C. Ascorbic acid and alpha-tocopherol as potent modulators of apoptosis on arsenic induced toxicity in rats. *Toxicol Lett.* 2005; 156 (2): 297-306.
24. Freedman JE, Keaney JF. Vitamin E inhibition of platelet aggregation is independent of Antioxidants. *J Nutr.* 2001; 131 (2): 3745-75.
25. Chinoy NJ, Sharma A. Amelioration of fluoride toxicity by vitamins E and D in reproductive functions of male mice. *Fluoride.* 1998; 31 (2): 203-16.
26. Al-Hiyasat AS, Elbetieha AM, Darmanib H. Reproductive toxic effects of ingestion of sodium fluoride in female rats. *Fluoride.* 2000; 33(6): 79-84.
27. Vani ML, Reddy KP. Effects of fluoride accumulation on some enzymes of brain and gastrocnemius muscle of mice. *Fluoride.* 2000; 33 (1): 17-26.
28. Sherlin DG, Verma RJ. Vitamin D ameliorates fluoride-induced embryotoxicity in pregnant rats. *Neurotoxicol Teratol.* 2001; 23 (2): 197-201.
29. Chattopadhyay A, Podder S, Agarwal S, Bhattacharia S. Fluoride induced histopathology and synthesis of stress protein in liver and kidneys of mice. *Arch Toxicol.* 2010; 85 (4): 327-35.
30. Verma RJ, Sherlin DM. Sodium fluoride-induced hypoproteinemia and hypoglycemia in parental and F (1)-generation rats and amelioration by vitamins. *Food Chem Toxicol.* 2002; 40 (12): 1781-8.
31. Tsunoda M, Aizawa Y, Nakano K, Liu Y, et al. Changes in fluoride levels in the liver, kidney, and brain and in neurotransmitters of mice after subacute administration of fluoride. *Fluoride.* 2005; 38 (4): 284-92.
32. Humayun F. Protective effect of ethanolic extract of propolis on isoniazid induced hepatotoxicity in male albino mice. MPhil Thesis. UHS, Lahore.2013.

- Received for publication: 18-10-2018
- First revision received: 10-01-2019
- Second revision received: 21-02-2019
- Accepted for publication: 12-03-2019